

Contents:

- ⊕ Blunt Carotid Injury
- ⊕ CXR and Blunt Aortic Injury
- ⊕ Case of the Month
- ⊕ What's new in Trauma?
- ⊕ Maria Seger Scholarship Reviewed
- ⊕ Meetings
- ⊕ Poetry in Motion

TRAUMA

Grapevine



Introduction

In this issue, articles report on a mixture of new and old topics, all emphasising the need for continual maintenance of skills and knowledge in trauma management. Chest Xrays are oft forgotten in the technological push we face, but they remain a cornerstone of the early evaluation of the trauma patient. An understanding of what is normal or abnormal is important and McIntosh and colleagues expands on this in the current issue. While blunt carotid artery injury is not new, it is not a well recognised entity, and I would commend Dubenec and colleague's review to you. Remember to look for blunt carotid injury in the next high risk patient you see.

Staff interchanges provide a wonderful opportunity for exchange in ideas and Tricia Ansell reflects on how she survived Liverpool during her month long position as the inaugural Maria Seger Scholar.

Looking to the future, now is the time to plan your free paper submission for the SWAN XI in August 2003.

Michael Sugrue



Blunt Carotid Artery Injury: A Review

Steven R. Dubenec, Eric Farmer, Gregory J. Leslie, John A. Crozier
Department of Vascular Surgery, Liverpool Hospital

Blunt carotid trauma comprises a small proportion of the injuries identified in trauma services. These injuries are important to diagnose because of their potential for significant morbidity and mortality. Morbidity rates of 40 – 80 % in association with blunt carotid cervical injury have been reported with most of these patients having a neurologic event. Mortality rates of between 5 – 40% have also been associated with this type of injury¹. These injuries have been thought to be rare, with an incidence of between 0.08 - 0.24%. However, this is before liberal screening in high-risk groups. The actual incidence of blunt carotid artery injury in the population remains unknown. When high-risk groups are screened with angiography an incidence of between 0.67 – 1.07 % of blunt trauma patients have a blunt carotid artery injury^{1,2}.

Mechanism of injury

These injuries occur because of either compression or extension of the carotid artery. The carotid artery is located anterior to the transverse processes of the cervical vertebrae. Injuries that cause hyperextension with or without rotation of the neck can stretch the carotid artery over these immobile anatomic structures, usually the third and fourth cervical vertebrae. The resultant forces can cause the intima, or in rare circumstances, the entire vessel to rupture. Compression injuries associated with flexion or extrinsic compression of the neck can compress the carotid artery against these bony structures and again injure the vessel.

These forces that cause hyperextension or compression of the neck occur in a wide range of trauma settings. Common scenarios include motor vehicle or motorbike accidents, pedestrian injuries, cranial injuries and hanging or strangulations.

High Risk Groups

Blunt carotid artery injuries can be asymptomatic in up to 50% of patients. In an early review of blunt carotid artery injuries (1967) it was shown that 50% of patients with these injuries had no external signs of neck trauma³. In 25 – 50% of patients with suspected blunt carotid artery injury they will also have a contralateral carotid artery injury¹.

Several high-risk groups have been identified and are shown in Table I. These patients with a neurological examination not consistent with cerebral CT scan, a lateralizing neurological deficit (including transient neurological deficits), unilateral Horner's Syndrome or anisocoria, cervical bruits, neck haematoma, pulsatile neck mass, base of skull fracture, severe facial fractures and head injuries with resultant Glasgow Coma Score of less than six have all been associated with an increased risk of blunt carotid artery injury^{2,4}. It has been demonstrated that these groups of patients



Blunt Carotid Artery Injury: A Review

Continued

should have screening for blunt carotid artery injury performed routinely. This is confirmed by Kerwin et al who investigated whether the liberalized screening for blunt carotid and vertebral artery injury is justified⁴. They showed that out of 48 patients screened, 21 patients (44%) had evidence on angiography of carotid or vertebral artery injury. Of this group 33% of the blunt carotid artery injuries were bilateral.

The mechanism of injury must also be considered. In patients in whom a significant mechanism has occurred they should also be considered for carotid artery injury screening.

Signs and Symptoms

Symptoms and signs associated with carotid artery injury can vary greatly. As stated previously up to 50% of patients with blunt carotid artery injury may be asymptomatic^{1,3}. Patients who display signs on physical examination may have local signs such as haematoma, pulsatile cervical mass, cervical bruit or excessive local bleeding. More generalised signs can range from loss of consciousness to focal neurological events. Physical signs themselves cannot be relied upon to identify patients with blunt carotid injury, because many will be asymptomatic. One must liberally screen for blunt carotid artery injury.

Investigation for Blunt Carotid Artery Injury

Modalities such as duplex ultrasound, computed tomography angiography (CTA), magnetic resonance imaging (MRI) and angiography are used to screen for blunt carotid artery injuries. The two most frequently used modalities are duplex imaging and angiography.

Carotid duplex is a rapid and non-invasive investigation that has a high sensitivity 92%¹. It has been disputed as having limitations in imaging the distal internal carotid artery and being unable to identify tight stenoses calling them occlusions. Other studies however have found carotid duplex accurate and advocate its use as a screening tool in the high-risk groups identified¹. Duplex ultrasound imaging of the at-risk stable trauma patient is the preferred investigation for blunt carotid artery injuries in zone II of the neck (between the cricoid cartilage and the angle of the mandible)⁵.

CTA has an increasing role in the early investigation of blunt carotid artery injury especially with new technological advances of new generation spiral CT. Rogers et al concluded that the use of CTA for diagnosing blunt carotid artery injury increased the diagnosis rate of these types of injury and have instituted CTA as part of their trauma protocol to evaluate patients with suspected blunt carotid artery injury⁶. It must be remembered though that duplex and angiography at present are still investigations of choice for investigating blunt carotid artery injury.

MRI is a non-invasive investigation that has a 95% sensitivity and 99% specificity for identifying injuries of the carotid artery⁷. MRI can also display the pathology of the carotid artery including intimal flaps. It has two major failings and these relate to the inaccessibility of the MRI and that they are expensive investigations.

Angiography is the gold standard. It has the best sensitivity and specificity of all the modalities, however, remains invasive with the possibility of its own complications including neurovascular events, arterial dissection and false aneurysms to name a few. It is also costly and time consuming. In the acute setting especially after hours where other investigative modalities may not be available angiography still remains the investigation of first choice unless duplex ultrasonography is available. Angiography is superior to duplex for injuries of zones I and III where bony structures may make insonation of these areas difficult. As technology progresses CTA or MRA may become better and more accessible and provide an investigation available twenty-four hours a day.

Classification of Blunt Carotid Artery Injuries

Classification of this injury and the resultant pathology is important as it has both treatment and prognostic significance. Biffi et al described a classification system that is both easy and can group patients with different injuries into treatment categories². There are five grades described and this is shown in Table 2. All patients in this study were anticoagulated with heparin unless a relative contraindication existed, then antiplatelet therapy was instituted and if an absolute contraindication existed patients were treated expectantly.

Biffi et al demonstrated that Grade I injuries predominately healed independent of heparinisation, with 7% of patients progressing to a higher grade injury². There was a 3% stroke risk associated with this group. Of the Grade II injuries all patients were heparinised and the majority (70%) progressed onto pseudoaneurysm or occlusion, only 10% of patients in this group had injuries that healed. The Grade III injuries had a high risk of rupture, thrombosis and embolism and surgical therapy was deemed as first line treatment. Lesions considered for surgery also needed to have the distal internal carotid artery accessible to surgery (not extending up to the skull base). Their experience reported an 89% success rate for endoluminal stenting of these injuries. Grade IV injuries were associated with a high stroke risk and should be anticoagulated as these injuries can recanalise with time. Finally the grade V injuries require prompt surgery with ligation, embolisation or balloon occlusion.

By subdividing carotid injuries into these groups shown, each type of injury is easily classified. Based on this, prognostic features can be applied and therapeutic options tailored to each individual case.

Management and Treatment

All blunt carotid artery injuries should be anticoagulated. If a relative

contraindication exists, antiplatelet therapy should be used instead^{2,8}.

Treatment of carotid artery dissection should be medical initially unless the dissection is associated with a luminal narrowing of $\geq 25\%$, intramural haematoma, intraluminal thrombus, or a raised intimal flap. Milder dissections with continuing or worsening symptoms may also require surgery. The lesion however, needs to be surgically accessible if surgery is contemplated. The surgical options available include carotid endarterectomy, carotid stenting, interposition vein or prosthetic graft and even internal carotid artery ligation with extracranial bypass if internal carotid artery back pressures are < 70 mmHg or the patient does not tolerate trial balloon occlusion whilst in angiography and without if back pressures are >70 mmHg and patient tolerates trial balloon occlusion.

Thrombosis of the internal carotid artery is mostly considered inoperable and anticoagulation the treatment of choice as there is small chance of recanalisation.

Summary

- 0.67 - 1.07% incidence of carotid artery injuries in blunt trauma patients.
- Screen high-risk patients (Table 1.) utilizing duplex ultrasound as soon as practicably possible.
- If indications for arch aortography co-exist then angiographic screening for blunt carotid artery injury should be considered.
- Early anticoagulation of grade I, II and IV carotid artery injuries is

Table 1. High Risk Groups for Blunt Carotid Artery Injury

Neurological examination not consistent with cerebral CT scan
Lateralizing neurological deficit (including TIA's)
Anisocoria
Cervical bruit
Neck haematoma / pulsatile neck mass
Base of skull fracture
Severe facial fractures
Glasgow Coma Score of less than six

Treatment options for pseudoaneurysms of the internal carotid artery are based upon the anatomical extent of the disease. If the pseudoaneurysm does not extend to the skull base then an interposition graft, aneurysmorrhaphy, excision and primary anastomosis and endovascular repair with either stents or coils are all acceptable options. If the pseudoaneurysm extends to the skull base then options depend upon internal carotid artery back pressures with ligation and anticoagulation used in patients with acceptable back pressures of > 70 mmHg and who tolerate a trial balloon occlusion of the internal carotid artery. If there is poor backpressure or if the patient fails a trial occlusion then ligation with extra cranial bypass may be required.

Rupture or transection of the internal carotid is often lethal and requires prompt surgical exploration. However, uncontrolled surgical decompression can rapidly convert a stable situation into a disaster². Balloon occlusion or endovascular embolisation may be appropriate alternatives to hazardous surgery if the patient is stable².

recommended when no contraindication exists.

- Prompt vascular surgical management optimises outcomes in carotid artery injury.

With a high index of suspicion and an aggressive diagnostic approach these injuries may be diagnosed earlier, prompting early treatment and, hopefully, decreasing the morbidity and mortality previously associated with them.

Table 2. Blunt Carotid Arterial Injury Grading Scale

Injury Grade Description	
I	Luminal irregularity or dissection $< 25\%$ luminal narrowing
II	Dissection or intramural haematoma with $\geq 25\%$ luminal narrowing, intraluminal thrombus, or raised intimal flap
III	Pseudoaneurysm
IV	Occlusion
V	Transection with free extravasation

Biffi et al. J Trauma. 1999;47(5):845-853



References

1. Kraus RR, Bergstein JM, DeBord JR. Diagnosis, treatment, and outcome of blunt carotid arterial injuries. *American Journal of Surgery* 1999; 178: 190-3.
2. Biffi WL et al. Blunt carotid arterial injuries: implications of a new grading scale. *Journal of Trauma-Injury Infection & Critical Care* 1999; 47: 845-53.
3. Yamada S, Kindt GW, Youmans JR. Carotid artery occlusion due to nonpenetrating injury. *Journal of Trauma-Injury Infection & Critical Care* 1967; 7: 333-42.
4. Kerwin AJ et al. Liberalized screening for blunt carotid and vertebral artery injuries is justified. *Journal of Trauma-Injury Infection & Critical Care* 2001; 51: 308-14.
5. Kumar SR, Weaver FA, Yellin AE. Cervical vascular injuries: carotid and jugular venous injuries. *Surgical Clinics of North America* 2001; 81: 1331-44.
6. Rogers FB et al. Computed tomographic angiography as a screening modality for blunt cervical arterial injuries: preliminary results. *Journal of Trauma-Injury Infection & Critical Care* 1999; 46: 380-5.
7. Levy C et al. Carotid and vertebral artery dissections: three-dimensional time-of-flight MR angiography and MR imaging versus conventional angiography. *Radiology* 1994; 190: 97-103.
8. Fabian TC et al. Blunt carotid injury. Importance of early diagnosis and anticoagulant therapy. *Annals of Surgery* 1996; 223: 513-22.



Are Chest X-rays of Value in the Evaluation of Blunt Trauma Victims to Diagnose Traumatic Aortic Injury?

MacKintosh Z,* Wilson S, Sugrue M. * University of Liverpool UK, Trauma Department Liverpool Hospital

Traumatic aortic rupture remains one of the most fatal injuries sustained in blunt trauma. A recent study of 387 blunt trauma deaths found aortic injury to be the most common cause of death behind head injury.¹ Although mercifully rare, the incidence of aortic injury is increasing in line with the incidence of motor vehicle accidents, a primary mechanism for the injury. Recent figures from the United States of America state that the incidence of the injury in this country is 8000 per year. Of these 8000, 1500 will reach hospital alive, the remainder dying on scene from exsanguination.² The rate of pre-hospital death is reported to be 80%.³ The increasing usage and availability of CT scanning has resulted in the use of chest x-rays in the diagnosis of traumatic aortic injury being questioned.⁴ Much has been written on this subject in recent years. This paper will review recent studies regarding the use of chest x-rays for this purpose and attempt to evaluate their place in the management of patients who are victims of blunt trauma.

Radiological Findings

A recent study by Cook et al reviewed radiological data to find the most common signs associated with blunt traumatic aortic laceration.⁴ These are shown in the table below. Their study contained 188 patients, 10 of whom were found to have blunt traumatic aortic laceration. The sensitivity and specificity shown are the results of their study. They found that the three most reliable signs were a mediastinum greater than 8 cm, a Mediastinum:Chest (M:C) ratio of greater than 0.25 and opacification of the aortopulmonary (AP) window. Their study

Sign	Sensitivity	Specificity
Mediastinum > 8 cm	0.90	0.30
M:C ratio > 0.25	0.90	0.06
Opacified AP window	0.90	0.51
Irregular aortic knob	0.80	0.68
Blurred aortic contour	0.70	0.53
Nasogastric tube deviation	0.50	0.91
Trachea shifted to patient's right	0.40	0.86
Pulmonary contusion	0.30	0.72
Wide left paraspinal line	0.29	0.90
Left apical cap	0.20	0.80
Any other rib fracture	0.20	0.70
Thoracic spinal fracture	0.11	0.93
Depressed left main bronchus	0.10	0.90
First rib fracture	0.10	0.91
Clavicle fracture	0	0.87

concluded that no individual radiographic sign was sufficiently sensitive for blunt aortic injury.

A study by Fabian et al of 259 patients with traumatic aortic rupture found the following features on chest radiograph.⁵

Finding	No. of patients (%)
Wide mediastinum	221 (85)
Indistinct aortic knob	63 (24)
Left pleural effusion	49 (19)
Apical cap	49 (19)
First and/or second rib fracture	33 (13)
Tracheal deviation	32 (12)
Depressed left bronchus	12 (5)
Nasogastric tube deviation	29 (11)
Negative x-ray	19 (7)

False-Negative Chest Radiographs

There have been several studies reporting incidences of false-negative chest radiographs. Results of some of these studies are given in the table below.

Author	Year	Normal Radiographs/Total (%)
Woodring et al ⁶	1989	6/32 (19)
Hilgenberg et al ⁷	1992	3/48 (6.2)
Higgins et al ⁸	1992	0/19 (0)
Walls et al ⁹	1993	4/27 (14.8)
Read et al ¹⁰	1993	3/16 (8)
Hunt et al ¹¹	1996	6/144 (4)
Fabian et al ⁵	1997	19/259 (7)
Gammie et al ³	1998	3/26 (12)
Santini et al ¹²	1999	3/39 (8)
Cook et al ⁴	2001	0/10 (0)

Sriussadaporn et al studied 9 patients regarding the significance of a widened mediastinum on chest x-ray and found that only 44% with traumatic aortic rupture had a widened mediastinum.¹³ Symbass et al studied 20 patients and found 6 with normal mediastinums. The authors stress that the presence of a normal mediastinum does not exclude the diagnosis of aortic rupture.¹⁴

Misawa et al report a case of a patient without chest pain or symptoms who had a normal chest radiograph.¹⁵ CT was performed due to the mechanism of injury (high-speed motor vehicle accident) despite lack of symptoms and revealed traumatic rupture of descending aorta. This case highlights the need to consider the possibility of aortic

rupture even then the chest x-ray is normal.

Negative Predictive Value of Chest Radiographs

There has been some discrepancy between studies regarding the negative predictive value of chest radiographs. Gammie et al highlight in their study that radiology literature suggests that a normal chest x-ray is evidence for the absence of underlying traumatic aortic injury.³ Mirvis et al found the negative predictive value of chest x-rays to be 98%.¹⁶ Cook et al state that none of their patients with proven blunt traumatic aortic laceration had a normal CXR and therefore negative predictive value was 100%, however, their study contained only 10 patients.⁴ A normal chest radiograph does not exclude the possibility of aortic injury. Another issue to consider here is the quality of the x-ray itself. Lee et al notes that mediastinal width is significantly affected by the degree of inspiration and position. They suggest that where clinically possible an upright inspiratory film be obtained to assess mediastinal width, however, they note that this is not always practical due to the fact that patients with this type of blunt trauma are frequently immobilised by spinal precautions.¹⁷

Mortality

Studies have estimated that the mortality of traumatic aortic injury, even in patients who reach hospital alive, is high. Certain studies have found rates of between 8 and 19%.^{3,5,12,13,14,18}

Savitt, reporting on a case of a patient with traumatic aortic rupture and a normal chest radiograph, states that a normal chest x-ray may delay diagnosis and increase morbidity and mortality.¹⁹ In the study of Gammie et al, the three patients with normal chest radiographs led to delays in treatment, and aortic repairs on those patients were carried out at 30, 33 and 127 hours post injury compared to an average of 5 hours for the rest of the patients in the study.³ Therefore, relying on chest radiograph in the process of diagnosing or excluding aortic injury may lead to an increase in mortality.

Mechanism of Injury

It is widely recognised that severe deceleration forces may lead to aortic injury but other mechanisms must also be considered. Reid et al report a case of a

patient with traumatic aortic rupture in a motor vehicle accident where the mechanism of injury was a low velocity crushing force.²⁰ The authors stress that these low speed impacts may also result in traumatic aortic rupture as well as more common severe deceleration forces.

Gammie et al detail the mechanism of injury for their 42 patients as follows: falls 3; pedestrian struck by car 1; hit by falling object 1; Motor Vehicle Accident 37. In their conclusion the authors state "A high level of suspicion is necessary to avoid the catastrophic results of missed aortic injury".³ Fabian also details the mechanism of injury for 274 patients: Motor Vehicle Accident 222 (72% head on; 24% side impact; 4% rear impact), Motor Bicycle Accident 19, Pedestrian struck by car 19, falls 7, other 7.⁵ Unfortunately, neither of these studies detail the mechanism of injury for the patients in whom chest radiograph findings were negative, however, their results do indicate the wide ranging possibilities of mechanism of injury in which a traumatic aortic injury may be sustained.

Alternatives to Chest Radiography

The gold standard for diagnosing aortic rupture remains aortography, with sensitivity of 100% and specificity of 90% reported.¹³ However, this is not a practical first line

option in most cases. Many studies now recommend CT scanning for stable patients, with favourable results reported.^{5,21,22} Dyer found negative predictive value of 100% for CT scanning in excluding traumatic aortic injury.²³ As the use of CT becomes increasingly available it will play a critical role in diagnosis in the future. In their recent article, Cook et al call for the implementation of large prospective multi-institutional outcome studies evaluating the utility of helical CT scans in the diagnosis of aortic injury in blunt trauma victims.⁴

Another emerging diagnostic tool is that of transoesophageal echocardiography, with sensitivities of between 0.80 and 0.87 reported.^{3,5}

Implications for Practice

Although the data reviewed above suggests that the chest radiograph should not be relied on for diagnostic purposes, it is still a useful part of everyday practice. Given that most trauma patients will undergo a trauma series of x-rays (chest, c-spine and pelvis) the chest radiograph will be taken anyway. In the study by Fabian et al, 85% of patients with aortic injury were found to have a widened mediastinum on chest x-ray, making the chest x-ray still a valuable indicator of aortic injury.⁵ While CT scanning is poised to become a useful screening tool for aortic

injury, the importance of the assessment of the patient as a whole, including a detailed history and careful consideration of the mechanism of injury, must not be underestimated. Patients who are unstable with clinical (or chest radiograph) signs of aortic injury should proceed to aortography without having a CT scan first.²³ In patients who are stable, a chest CT may be used to assist diagnosis, but aortography remains the gold standard.

The assessment of patients who are suspected of having blunt aortic injury largely depends on the facilities available. The most important issue here is staffing, using correct scanning protocols and specialist reporting on the images.

Therefore, the main recommendations for practice in cases of suspected blunt aortic injury are as follows:

- A chest x-ray should be performed on arrival, but the result, if negative, should not be used to exclude a diagnosis of blunt aortic injury.
- If patients are stable, all those with a significant mechanism of injury or clinical signs of chest trauma should have a CT scan performed. In high risk patients angiography is still the test of choice in most hospitals.



References:

1. Smith RS, Chang FC. Traumatic rupture of the aorta: Still a lethal injury. *American Journal of Surgery*. 1986;152:660.
2. Fischer PJ, Kent RB. Combined blunt thoracic aortic and abdominal trauma: Diagnostic and treatment priority. *Southern Medical Journal* 2000;93(9):865-7.
3. Gammie JS, Shah AS, Hattler BG, Kormos RL, Peitzman AB, Griffith BP, Pham SM. Traumatic aortic rupture: Diagnosis and management. *Annals of Thoracic Surgery*. 1998;66(4):1295-1300.
4. Cook AD, Klein JS, Rogers FB, Osler TM, Shackford SR. Chest radiographs of limited utility in the diagnosis of blunt traumatic aortic laceration. *J Trauma*. 2001;52:843-847.
5. Fabian TC, Richardson JD, Croce MA, Smith JS, Rodman G, et al. Prospective study of blunt aortic injury: Multicenter trial of the American association for the surgery of trauma. *J Trauma-Injury Infection & Critical Care*. 1997;42(3):374-383.
6. Woodring JH, King JG. The potential effects of radiographic criteria to exclude aortography in patients with blunt chest trauma. Results of a study of 32 patients with proved aortic or brachiocephalic arterial injury. *J Thoracic and Cardiovascular Surgery*. 1989;97:456-460.
7. Hilgenberg AD, Logan DL, Akins CW. Blunt injuries of the thoracic aorta. *Annals of Thoracic Surgery*. 1992;53:233-239.
8. Higgins RS, Sanchez JA, DeGuidis L. Mechanical circulatory support decreases neurologic complications in the treatment of traumatic injuries to the thoracic aorta. *Archives of Surgery*. 1992;127:516-519.
9. Walls JT, Boley TM, Curtis JJ, Schmaltz RA. Experience with four surgical techniques to repair traumatic aortic pseudo-aneurysm. *J Thoracic and Cardiovascular Surgery*. 1993;106:283-287.
10. Read RA, Moore EE, Moore FA, Haenel JB. Partial left heart bypass for thoracic aorta repair: Survival without paraplegia. *Archives of Surgery*. 1993;128:746-752.
11. Hunt JP, Baker CC, Lentz CW. Thoracic aorta injuries: Management and outcome of 144 patients. *J Trauma*. 1996;40:547-556.
12. Santini F, Gatti G, Cannarella A, Mazucco A. Diagnosis and early surgical management of traumatic thoracic aortic disruption. *Giornale Italiano di Cardiologia*. 1999;29(12):1426-1430.
13. Sriussadaporn S, Luengtaviboon K, Benjacholamas V, Singhatanadgige S. Significance of a widened mediastinum in blunt chest trauma patients. *J Medical Association of Thailand*. 2000;83(11):1296-1301.
14. Symbas PJ, Horsley WS, Symbas PN. Rupture of the ascending aorta caused by blunt trauma. *Annals of Thoracic Surgery* 1998;66(1):113-117.
15. Misawa Y, Fuse K, Kamisawa O. Asymptomatic traumatic aortic rupture. *Annals of Thoracic Surgery*. 1999;68(2):628-629.
16. Mirvis SE, Bidwell JK, Buddemeyer EU, et al. Value of chest radiography in excluding traumatic aortic rupture. *Radiology*. 1987;163:487-493.
17. Lee FT, Katzberg RW, Gutierrez OH, Burgener F, Yee WK, Morris T, Bronson JP. Reevaluation of plain radiographic findings in the diagnosis of aortic rupture: The role of inspiration and positioning on mediastinal width. *J Emergency Medicine*. 1993;11(3):289-296.
18. Tatou E, Steinmetz E, Jazayeri S, Benhamiche B, Brenot R, David M. Surgical outcome of traumatic rupture of the thoracic aorta. *Annals of Thoracic Surgery*. 2000;69(1):70-73.
19. Savitt DL. Traumatic aortic rupture: Delayed presentation with a normal chest radiograph. *American Journal of Emergency Medicine*. 1999;17(3):285-287.
20. Reid C, Livesey SA, Egleston CV. Aortic rupture as a result of low velocity crush. *Emergency Medicine Journal*. 1999;16(4):299-300.
21. Ledbetter S, Stuk JL, Kaufman JA. Helical (spiral) CT in the evaluation of emergent thoracic aortic syndromes. Traumatic aortic rupture, aortic aneurysm, aortic dissection, intramural haematoma and penetrating atherosclerotic ulcer. *Radiologic Clinics of North America*. 1999;37(3):575-589.
22. Sebastia C, Pallisa E, Quiroga S, Alvarez-Castells A, Dominguez R, Evangelista A. Aortic dissection: Diagnosis and follow-up with helical CT. *Radiographics*. 1999;19(1):45-60.
23. Dyer DS, Moore EE, et al Thoracic aortic injury: How predictive is mechanism and is chest computed tomography a reliable screening tool? A prospective study of 1,561 patients. *J Trauma-Injury Infection & Critical Care*. 2000;48(4):673-683.



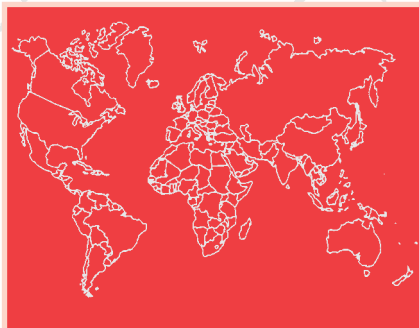What's New in Trauma

A New Screw Catheter Kit for Bedside Treatment of Chronic Subdural Haematomas

Benes L et al Department of Neurosurgery Philipps-University Hospital Maburg Germany

The authors describe a New Screw Catheter Kit using a twist-drill trephination with a newly developed screw catheter kit allowing bedside evacuation of chronic subdurals. The screw has an outer diameter of 5 mm, a silicone catheter and a collection bag. Under local anaesthetic the trephination occurs and then the plastic bolt is screwed in place. The 3 mm silicone catheter is passed intracranially. They evaluated this technique on eight patients, mean age 69 years, all with chronic subdural haematomas. While their outcomes are a little bit difficult to determine from their article, it would appear that the procedure was affective in 75% of patients. Their argument was that conventional operative technique of craniotomy and membranectomy described by Tyson in 1980 has a significant mortality rate. The twist-drill craniostomy of chronic subdural haematoma and closed suction drainage was outlined by Tabaddor in 1977 suggesting it was superior to other means. Closed system drainage is capable of reducing the haematoma recurrence rate to around 3-4%. The plastic screws used by Benes and colleagues do not cause any artefact on CT scan. They would advocate that their new technique for draining subdural haematoma of a chronic nature is particularly useful.

J Trauma 2002; 52:591-594



Arterial Blood Gas Analysis in the Initial Evaluation of the Nonintubated Adult Blunt Trauma Patient

Barquist E et al University of Rochester

In this prospective study evaluating arterial blood gases in the care of the adult non-intubated trauma patient Barquist and colleagues evaluated 116 nonintubated trauma patients with blood gas studies in the Emergency Department. In their study arterial blood gases detected unsuspected metabolic acidosis in 18% of the nonintubated patients and found profound arterial hypercarbia in 3 patients. They concluded that arterial blood gas analysis should be performed on all the nonintubated seriously injured blunt trauma patients who meet trauma team activation criteria.

J Trauma 2002;52:601-602

Time to Laparotomy for Intra-abdominal Bleeding from Trauma Does Affect Survival for Delays Up to 90 Minutes

Clarke J et al

Clarke and colleagues from MCP-Hahnemann University, Philadelphia undertook a review of the Pennsylvania trauma system registry to determine the relationship between survival and time in the Emergency Department before laparotomy for hypotensive patients bleeding from abdominal injuries. They looked at patients with isolated abdominal vascular injury, solid organ injuries, abdominal wall injuries grade 3-6 and hypotension. Deaths were predicted from the pre-hospital time, systolic blood pressure and the time in ED before either laparotomy or ED death. 243 patients met the criteria with time to the ED from 7-185 minutes and time in the ED ranging from 7-915 minutes. Overall 40% of the patients died. Logistic regression of the 165 patients spending 90 minutes or less in the ED showed that the probability of death increased with time in the ED. The increase was as much as 0.35% per minute. They concluded among patients in a trauma registry who are hypotensive on arrival in the ED and in major injuries isolated to the abdomen requiring emergency laparotomy, the probability of death showed a relationship to both the extent of hypotension and the length of time in the ED for patients who were in the ED for 90 minutes or less. The probability of death increased approximately 1% for each 3 minutes in the Emergency Department.

J Trauma 2002;52:420-425



MARIA SEGER MEMORIAL TRAUMA NURSING SCHOLARSHIP

As the first recipient of the Maria Seger Nursing Scholarship, I was fortunate to spend 4 weeks at the Liverpool Hospital during May of this year. Through this experience I have gained valuable insights into the similarities and the differences in trauma care between my place of work, Barwon Health in Geelong, Victoria and that delivered in New South Wales. This work placement meets a recent recommendation by the Victorian ROTES report, and that is to deliver trauma education through rotating staff through major trauma services.

Upon my arrival at Liverpool I was made to feel part of the process. I was given opportunities to join the trauma rounds each morning, attend trauma audits and in-service education, work with trauma co-ordinators and meet with nurse managers and of course attend trauma calls. The trauma calls were many and varied. I found the opportunity to observe a patient's progression through the complete care continuum, including pre-hospital setting, emergency room, theatre, ICU and trauma wards to be most beneficial.

This scholarship has proven to be very beneficial for my own professional development and will be important to our department and the region as recommendations are implemented. Some of the successful guidelines in use at Liverpool can be utilised in our region, however it is important to appropriately adapt protocols to one's own practice area rather than merely replicate.

During my visit, Liverpool underwent verification of their trauma system, the first hospital to be involved in this process. Verification examines the capacity of the Trauma Department to treat critically injured trauma patients, and focuses on patient outcomes. It was interesting to listen to the questioning and expectations of the Verification team.

A day out with Careflight was exciting as I had the chance to observe the crew involved in a

primary rescue in a nature reserve. Ridealongs with a paramedic crew from Green Valley was also a highlight, with the paramedics talking through their protocols as they used them, explaining their rationale at each juncture. The real education in both these experiences was seeing how other professional teams work together and the interaction between the different disciplines. This opportunity served to emphasise the importance of understanding and appreciating the work environment of our colleagues in patient care. A visit to the Ambulance Control Centre completed the circle of prehospital management.

I visited other hospitals in the South Western Sydney Area. Viewing other emergency departments (Bowral, Cambelltown and Fairfield) in the area gave another dimension to the management of trauma patients and the system of bypass and transferring of patients to a Major Trauma Service. I also visited a Major Trauma Service in another area, St. George hospital. Comparing these two departments and major trauma services was interesting, as I discovered that all the processes are not necessarily exactly the same.

While at Liverpool I was given the opportunity to conduct a research project, looking at intravenous cannulation fixation in trauma patients. Participating in this project was an education in itself, having not been actively involved in research at the grass roots before.

The experience at Liverpool was rewarding and worthwhile. I would like to thank the many people in the Trauma and Emergency Departments who made me feel welcome and willingly shared their knowledge and expertise with me. I would highly recommend this type of exchange to any nurse who is involved in the management of trauma patients, and would encourage them to apply for this scholarship in the future.

Tricia Ansell, Geelong

Case of the Month

Martin Heetveld, Trauma Department

23 year old male, accident time 14.30

M Driving a bush buggy in a country paddock. Hit something and rolled over. Protective upper bar of buggy crushed mid-chest zone. Buggy weight: 400 kg. At scene for 1 hour before found.
I Bilateral chest pain and shortness of breath
S HR; 100/min, BP; 130/-. RR 30/min, GCS 14, No LOC
T Oxygen, C collar

Primary Survey at Remote Hospital at 16.30

Airway: Intact
Breathing: RR; 30/m, diagnosed with bilateral pneumothorax and lower rib # left After bilateral chest ????? insertion – equal AE and Sats; 99% on 10l Oxygen
Circulation: P95/m, BP; 120/-
Disability: GCS 15, PEARL
No gross neurological symptoms present

Medical Retrieval transfer from Rural Hospital at 11.00, Pt was intubated for transfer flight

Primary Survey at Liverpool at 11.50

Airway: ETT
Breathing: Bilateral ICC, equal AE, Sats 100% on 10l Oxygen
Circulation: P90/m, BP 120/-
Disability: Sedated
First CXR at Liverpool (figure 1).

Secondary survey: no head injury, no steps in the cervical, thoracic or lumbar spine, subcutaneous emphysema left side chest, non-distended abdomen, possible injury to right AC joint or upper humerus, pelvis and lower extremities normal. FAST was negative. Blood gas analysis was normal. The lateral C-spine film and the AP pelvic films were both normal. A less rotated CXR was taken later in the clinical course (figure 2).

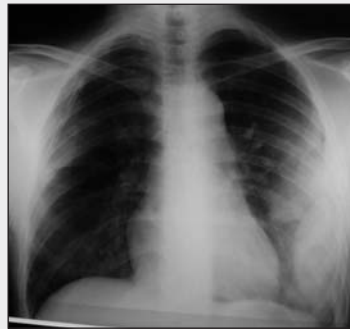

Figure 1

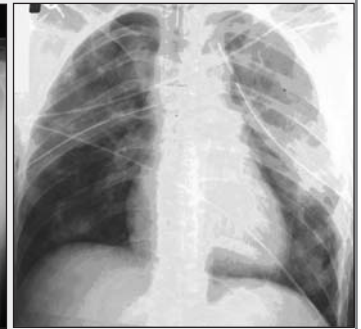


Figure 2

What would you do next?

- What potential injuries does this patient have?
- Should the patient be extubated rapidly?
- What further imaging should take place and what should be imaged?

For more information, see next issue.

Meetings



Definitive Surgical Trauma Care Course (DSTC)

Liverpool: 30/31st July 2003
Contact: Michael Sugrue or Charmaine Miranda (61 2) 9828 3928
Email: charmaine.miranda@swsahs.nsw.gov.au
Melbourne: 11th & 12th November, 2002
Contact: Peter Danne or Judy Forsyth (61 3) 9342 7232
Email: Judy.Forsyth@mh.org.au

WORLD CONGRESS on the ABDOMINAL COMPARTMENT SYNDROME

A comprehensive overview of the Abdominal Compartment Syndrome and Intra-Abdominal Hypertension, Damage Control and Temporary Abdominal Closure.

6th – 8th December, 2004

Noosa, Queensland, Australia

Keynote Speakers: Nth America – Michael Chang, Michael Cheatham, Scott D'Amours, Rao Ivatury, Harvey Sugarman; South America – Paulo Cesar Pereira de Souza; Europe – Kenth Johansson, Karel Kolkman, Ari Leppaniemi, Manu Malbrain, Paolo Pelosi; Africa – David Muckart; Australasia – Mike Hunter, Stephen Deane, Michael Parr, Gillian Bishop, Michael Sugrue, Felicity Jones.

For further information contact:

Charmaine Miranda, Congress Secretary

Ph: 61 2 9828 3928

Fx: 61 2 9828 3926

Email: charmaine.Miranda@swsahs.nsw.gov.au

Web: <http://www.swsahs.nsw.gov.au/livtrauma>

SWAN 11 Call for papers

SWAN 11 will be held on the 1st and 2nd of August, 2003, with 9 confirmed international leaders in Trauma. Registration is limited, so get in early!

Contact: Thelma Allen

Email: thelma.allen@swsahs.nsw.gov.au

Phone: (61 2) 9828 3927

<http://www.swsahs.nsw.gov.au/livtrauma>

It's An Incident!

By: M. GENNAOUI

*Buzz! Buzz! Buzz!
The alarm clock goes.
We stagger out off bed
And ready for work we all get.
We cannot be late
As we all have a date
With a scope or a blade.*

*Beep! Beep! Beep!
The patient is relaxed and quite deep
In a sweet gentle kind of sleep.
The operating room is disturbed
By the shriek of laughter from a joke
And our tears are causing us to choke.*

*An incident report must be written
for the respect the patient was not given.*

*Ring! Ring! Ring!
The mobile phone rings.
"Hello ... " - only bad news it brings.*

*An incident report must be written
And a misconduct warning be given.*

*Consent for this, consent for that!
Consent forms are a real art!
Your form or mine
The line is very fine.*

*Fill out an incident report
Just in case we all end up in court.*

*Oh little nurse,
A truck full of Mars bars
is what you need
to make you sweet.*

*An incident report must be written
For the cheek the nurse was given.*

*If doctor is five minutes late
And for him we all have to wait
If it's not because he is dead
And it is more than we can bear
Then, we believe that it is only fair*

*That an incident report be written
And to the boss it be given.*

Remember if you are not a member of Australian Trauma Society - you could be!

Gelofusine[®]

Modified Fluid Gelatin



The Premium Gelatin Colloid

PBS General Benefit: 500ml x 3 bottles

B | BRAUN
HOSPITAL CARE

The Trauma Department would like to acknowledge the support of
B.Braun Australia Pty Ltd
producers of Gelofusine[®] in the publication of the Trauma Grapevine

©1996 Trauma Department Liverpool Letters to Dr Michael Sugrue
Trauma Department, Liverpool Hospital,
Elizabeth Street NSW 2170 Fax 9828 3922

www.swsahs.nsw.gov/livtrauma Email: michael.sugrue@swsahs.nsw.gov.au

The Trauma Grapevine is owned, published, copyrighted © 2001 It is sponsored by B Braun All rights reserved.
Editorial Offices: Trauma Department Liverpool Hospital Locked bag 7103 Liverpool BC 1871 Australia Phone: (61) 2 98283927 FAX: (61) 2 98283926
Editorial Board Scott D'Amours Trauma Surgeon Liverpool Hospital, Tim Hodgetts Professor Emergency Medicine Birmingham, Kenth Johansson, General and Trauma Surgeon Vastervik Sweden, Karel Kolkman, Trauma Surgeon Holland, Martin Jones Rural Surgeon Nowra NSW, Kathy Martin Trauma Coordinator Philadelphia USA Michael Sugrue Trauma Surgeon Liverpool, Don Trunkey Trauma Surgeon Oregon USA. ISSN 1329-2846